

Technique—Patient Outlook

## Endonasal transsphenoidal surgery: the patient's perspective— survey results from 259 patients

Joshua R. Dusick, MD<sup>a</sup>, Felice Esposito, MD<sup>a,b</sup>, Carlos A. Mattozo, MD<sup>a,b</sup>,  
Charlene Chaloner, RN<sup>a,b</sup>, David L. McArthur, PhD, MPH<sup>a</sup>, Daniel F. Kelly, MD<sup>a,b,\*</sup>

<sup>a</sup>Division of Neurosurgery, University of California at Los Angeles School of Medicine, Los Angeles, CA 90095-7182, USA

<sup>b</sup>UCLA Pituitary Tumor and Neuroendocrine Program, Los Angeles, CA 90095-7182, USA

Received 13 October 2005; accepted 19 December 2005

### Abstract

**Background:** Patient impressions remain an important yet often overlooked aspect of surgical success. Herein we present postoperative questionnaire results in patients after a standard direct endonasal approach, an extended suprasellar endonasal approach, and a reoperative transsphenoidal surgery for tumor removal with the operating microscope.

**Methods:** From July 1998 through April 2005, of 452 patients undergoing endonasal surgery, 346 were sent questionnaires, and of these, 259 (75%) completed them. Nasal packing was placed for 24 hours in the first 95 patients but not in the last 357.

**Result:** Overall, 73% of patients reported a better experience than expected and 8% worse than expected. A worse than expected overall experience was noted in 15% of patients with nasal packing compared with 5% of patients without packing ( $P = .001$ ). Of patients with preoperative headache, 49% resolved, 34% somewhat resolved, and 5% worsened. The frequency of rhinological complaints declined from 2 weeks to 3 months postsurgery ( $P < .001$ ); by 3 months or more postsurgery, 67% to 87% of patients had no rhinological complaints and 1% to 2% had severe complaints. Of 30 patients with prior sublabial surgery, the endonasal procedure afforded easier recovery (87%), less pain (80%), better nasal airflow (79%), and a shorter hospital stay (median 3 vs 5 days) ( $P < .001$ ). Of 28 patients with complications, the severity of rhinological complaints was similar to those without complications except this subgroup reported greater loss of sense of smell 3 months after surgery ( $P < .001$ ).

**Conclusions:** Rhinological recovery is typically rapid and relatively complete after direct endonasal transsphenoidal surgery using both standard and extended suprasellar approaches. Compared with the sublabial route, the endonasal approach is associated with less pain, better nasal airflow, and a shorter hospital stay.

© 2006 Elsevier Inc. All rights reserved.

### Keywords:

Endonasal transsphenoidal surgery; Transnasal approach; Pituitary adenoma; Extended transsphenoidal approach; Patient survey; Complications

### 1. Introduction

A direct endonasal approach to the sella requiring removal of the middle turbinate and part of the nasal septum was first described by Hirsch in 1910 [31,32]. In 1912, Cushing introduced the sublabial transsphenoidal

approach. Inadequate lighting, instruments, and magnification made the transsphenoidal approach difficult at that time, and it was largely abandoned until Dott, Guiot [20], and Hardy [21,22] repopularized the sublabial approach in the 1950s and 1960s [31,32]. Although the sublabial approach has been the favored route to the sella for many subsequent years, an endonasal approach with the operating microscope and more recently with the endoscope alone or an endoscope-assisted approach has gained in popularity, both for neurosurgeons and their patients [8,13,23,24,41].

\* Corresponding author. 200 UCLA Medical Plaza, Suite 504, Los Angeles, CA 90095-7182, USA. Tel.: +1 310 206 0344; fax: +1 310 206 8581.

E-mail address: [dkelly@mednet.ucla.edu](mailto:dkelly@mednet.ucla.edu) (D.F. Kelly).

The endonasal approach currently used by many pituitary surgeons was first described by Griffith in 1987 as a refinement of Hirsch's original approach [18]. Requiring minimal mucosal dissection, this direct endonasal technique avoids the extensive mucosal elevation required of the sublabial and endonasal transcolumellar (transseptal) approaches. Instead of three mucosal tunnels as in the sublabial route or one mucosal tunnel in the transseptal approach, the direct endonasal approach requires no mucosal tunnels and only one mucosal incision is made in the posterior nasal cavity [12,18,36,41]. Although the sublabial route may provide slightly wider anatomical exposure than the endonasal approach [12,36], this difference is likely clinically negligible based on success rates for removal of sellar and parasellar tumors using this approach [1-4,14,25-27,41]. However, rhinological recovery after both the sublabial and transseptal endonasal approaches appears to be associated with a relatively high rate of rhinological complaints and complications such as upper lip and teeth numbness, septal deformities, and perforations [10,12,15,34,35,37,38,41].

We have been using the direct endonasal approach for all pituitary tumors and many parasellar tumors for almost 7 years, and in 2003 demonstrated the efficacy of this approach in our first 100 treated patients [41]. Questionnaire results completed by a subset of patients indicated the endonasal route was generally preferred over the sublabial route. With over 3 years of additional experience and over three times as many patient surveys, we present a reassessment of patient impressions of this approach including subanalyses of patients with (1) prior sublabial surgery, (2) an extended approach for suprasellar lesions, (3) a relaxing alar incision (alotomy), and (4) those with Cushing's disease. Given that not all patients completed questionnaires, we also included an analysis of patients with surgical complications to mitigate the potential for selection bias.

## 2. Methods

### 2.1. Patient population

All patients who had endonasal surgery for a pituitary adenoma or other parasellar tumor, including extended and transclival procedures, at UCLA or Harbor-UCLA Medical Centers between July 1998 and April 2005 were eligible for study. Patients with primary cerebrospinal fluid (CSF) leak repairs or sphenoid sinus biopsies were excluded. Patient charts were reviewed to document length of stay and surgical complications; surgical remission rates for the various tumor types were not included given that this material has, in part, been presented previously and to maintain focus of this study [14,41]. The senior author (DFK) performed all procedures. The investigational review boards of UCLA and Harbor-UCLA Medical Centers approved this study.

### 2.2. Questionnaire

A letter was mailed to patients requesting consent to participate in the study. Consenting patients were mailed a 21-point questionnaire to be completed at their leisure or, in some cases, over the telephone by office personnel. As in our original report using this survey, patients were asked to rate their overall surgical experience and characterize the most unpleasant aspects of their hospital stay [41]. They were also asked to quantify the degree of postoperative discomfort (none, mild, moderate, or severe) at 2 weeks and at 3 months or more after surgery for new headaches and for 5 areas related to rhinological recovery including facial pain, nasal congestion, decreased nasal airflow, decreased sense of smell, and upper lip numbness. As surveys were administered only once per patient, the answers regarding discomfort at 2 weeks after surgery were retrospective in nature. Patients who had previous sublabial surgery completed an additional section to compare their sublabial and endonasal surgical experiences in terms of postoperative pain, nasal airflow, and ease of recovery.

### 2.3. Rhinological details of the endonasal approach

The technical details of the standard direct endonasal approach with the operating microscope (and in some cases with endoscopic assistance) and the extended transsphenoidal approach for suprasellar and transclival lesions have been described previously [11,14,16,41]. However, a few key points regarding rhinological aspects of the approach warrant emphasis. First, the initial preparation of each nasal cavity involves only a brief swabbing with betadine-soaked cotton-tipped applicators; no topical decongestants or injected vasoconstrictors are used. Second, during the initial approach (performed with the microscope), care is taken to minimize mucosal trauma and bleeding from the hand-held speculum and during insertion of the modified Hardy speculum (Mizuho America, Inc, Beverly, Mass). Third, in gaining exposure of the sphenoid keel and ostia, the only mucosal incision deliberately made is at the junction of the posterior nasal septum and sphenoid keel. The mucosal flaps are reflected bilaterally by the speculum blades and in some areas are cauterized with the bipolar and removed with microscissors or a rongeur. Fourth, upon entering the sphenoid sinus, the only mucosa typically removed is that lining the anterior sphenoid sinus wall and overlying the sella; the remainder of the sphenoid sinus mucosa is left intact. Fifth, at the completion of the procedure, after removing the modified Hardy speculum, the hand-held speculum is again used to explore both the operated and nonoperated nasal cavities with the operating microscope to identify significant mucosal bleeding, which is stopped with the bipolar, Gelfoam or Surgifoam. Hemostasis should be sufficient at closure so that blood is not visibly welling up in the sphenoid sinus. Sixth, the middle turbinate on the side of the approach, which is out-fractured by the speculum at the

Table 1  
Pathological diagnoses in 259 patients

Pathology	No. of patients
Pituitary adenoma	203
Endocrine-inactive	106
Prolactinoma	42
Cushing's disease	36
Acromegaly	18
TSH secreting	1
Rathke's cleft cyst	23
Craniopharyngioma	10
Meningioma	5
Chordoma or other clival mass	6
Sphenoid sinus carcinoma	4
Other	8
Total	259

start of the procedure, is repositioned by medializing it toward the nasal septum; this maneuver helps avoid development of a maxillary sinus mucocele. Lastly, the nasal septum is returned to the midline. In the first 95 patients of our series (79 of which completed questionnaires), nasal packing was placed for 24 hours in the subsequent 357 patients, nasal packing was not used. During the first postoperative night, patients are given a humidified face tent and decongestants are available upon request. Antibiotics are given for 24 hours after surgery. Saline nasal spray is provided for a week after surgery and used based on patient preference.

#### 2.4. Statistical analysis

Differences between groups for numerical data (eg, hospital length of stay) were determined by analysis of variance. Differences between groups (sublabial vs endonasal, patients with complications vs patients without complications, and standard endonasal approach vs the extended suprasellar endonasal approach) for questionnaire items with categorical responses (eg, none, mild, moderate, or severe) were tested by the  $\chi^2$  test and Fisher exact test. The Rasch model (Bigsteps, University of Chicago, Ill) of quality control and psychometric testing was used to test the internal consistency of the questionnaire items related to recovery after surgery [6,30,40].

### 3. Results

#### 3.1. Study population

##### 3.1.1. Response rate

A total of 452 patients underwent endonasal procedures during the study period. Two patients were unable to complete the questionnaire because of cognitive difficulties unrelated to their pituitary disorder. One patient was unable to effectively complete the questionnaire because of severe trigeminal pain unrelated to her surgical procedure. Ten patients had been lost to follow-up and two patients had died of unrelated causes. An additional 91 patients were

not sent questionnaires because they fell within periods of time during which there was insufficient staffing to contact patients and administer questionnaires; this left a total of 346 eligible patients, 259 of which completed questionnaires (75% response rate); 75 patients failed to respond to the initial mailings, 7 declined to participate, and 5 initially agreed to participate but never returned the questionnaire.

##### 3.1.2. Demographics

Of the 259 patients who completed questionnaires, there were 156 (60%) females and 103 (40%) males with a mean age of 47.7 years (range, 10–87 years). Pathology included 203 (78.4%) pituitary adenomas, 23 (9%) Rathke's cleft cysts, 10 (4%) craniopharyngiomas, 5 (2%) meningiomas, 6 (2%) chordomas or other clival masses, 4 (1.5%) sphenoid sinus carcinomas, and 8 (3.1%) other lesions including arachnoid cysts, dermoid cyst, histiocytosis, and fibrous dysplasia (Table 1).

##### 3.1.3. Length of stay and complication rate

Median hospital length of stay for all 259 patients was 3 days (range, 1–25 days), with more than 86% of patients going home by day 4. (Fig. 1) Twenty-eight (10.8%) patients had surgical complications, the most common of which were persistent diabetes insipidus (3.9%), postoperative CSF leak (3.1%), and anterior hypopituitarism of one or more hormonal axis (1.5%). In addition, there were 15 (5.8%) patients with transient postoperative hyponatremia, 5 (1.9%) of whom required readmission for observation and treatment. In the entire cohort of 452 cases, there were 3 (0.7%) carotid artery injuries (without neurological sequelae), 2 postoperative sellar hematomas, and 3 endoscopic sinus surgeries including 2 for mucocele formation and 1 for chronic rhinitis and congestion. There were no permanent ocular palsies, visual worsening, or mortalities. Of the 193 patients who did not complete questionnaires, 14% had surgical complications, similar to the rate in the surveyed group ( $P > .2$ ) (Table 2).

##### 3.1.4. Surgical approach and prior surgery

Of 259 patients completing questionnaires, 15 (6%) had an extended transsphenoidal approach for a suprasellar nonadenomatous tumor (including tuberculum sellae meningioma, craniopharyngioma, supraglandular Rathke's cleft cyst, or dermoid cyst) [11,14]. Fifty-six (22%) patients had undergone at least one previous surgery at an outside hospital. Of these patients, 55% had undergone a sublabial procedure, 30% an endonasal procedure, and 27% a craniotomy (some patients had more than one procedure). Of the 259 patients surveyed, 58% had an intraoperative CSF leak, 26% had abdominal fat grafts placed for intraoperative CSF leak repair, and 8% had transient lumbar CSF diversion. Only 16% required a small relaxing alar incision (alotomy); however, none of the last 172 patients have had an alotomy.

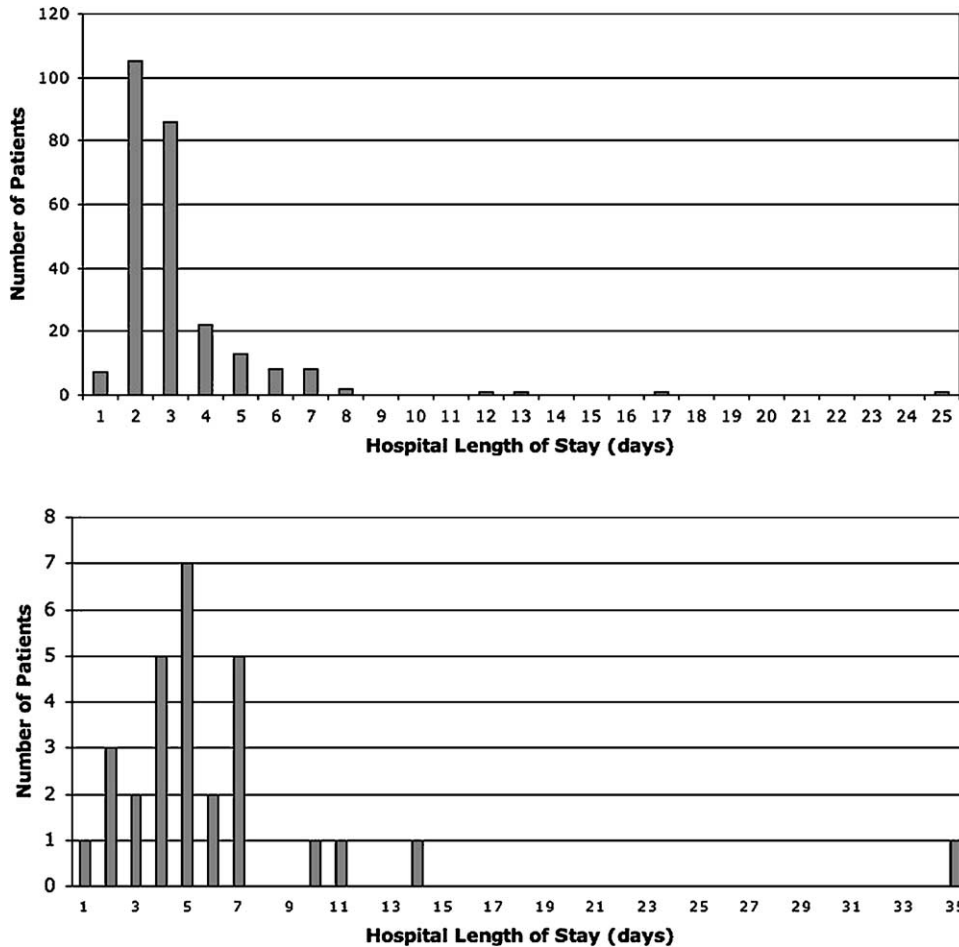


Fig. 1. Hospital length of stay for all 259 patients surveyed (top; median stay, 3 days; range, 1-25 days) and for previous sublabial procedures (bottom; median stay, 5 days; range, 1-35 days;  $P < .001$ ). Overall, 86% of patients were discharged by postoperative day 4.

3.2. Questionnaire results

3.2.1. Entire cohort

Overall, 73% of patients said the surgical experience (surgery, hospitalization, and recovery) was better than expected, whereas 19% said it was the same and 8% said it was worse than expected. Regarding the in-hospital postoperative period, the most common sources of discomfort were mouth breathing and/or dry mouth (37%) and headache (38%). Preoperatively, 55% of all patients had headache; of these, 49% said their headaches completely resolved, 34% somewhat resolved, 12% had no change, and 5% worsened.

The frequency of all postoperative complaints, including headache and facial and sinonasal complaints, declined significantly from 2 weeks after surgery to 3 months or more after surgery ( $P \leq .001$ ) (Fig. 2). At the 3-month postoperative time point, patients quantified these problems as follows: new headache—none 64%, mild 22%, moderate 12%, and severe 2%; facial pain—none 85%, mild 9%, moderate 4%, and severe 2%; nasal congestion—none 67%, mild 20%, moderate 11%, and severe 2%; decreased nasal airflow—none 76.5%, mild 15%, moderate 6.5%, and

severe 2%; decreased sense of smell—none 77.2%, mild 12.4%, moderate 8%, and severe 2.4%; upper lip numbness—none 87%, mild 10%, moderate 2%, and severe 1%.

Sixty-one percent of patients reported returning to work or school within 1 month of surgery, and 74% returned by 2 months (Fig. 3). Twelve percent ( $n = 30$ ) of patients reported they were still unable to return to work at the time of completing the questionnaire. However, 80% of these

Table 2  
Complications in patients answering questionnaires

Complication	No. of patients
None	231 (89%)
Persistent DI	10
CSF leak	8
Loss of anterior pituitary axis	4
Epistaxis	3
Hematoma/hemorrhage	2
Sinusitis	2
Meningitis	1
Pneumonia	1
Suprasellar fat graft too big	1
Pulmonary embolus	1
Carotid injury	0

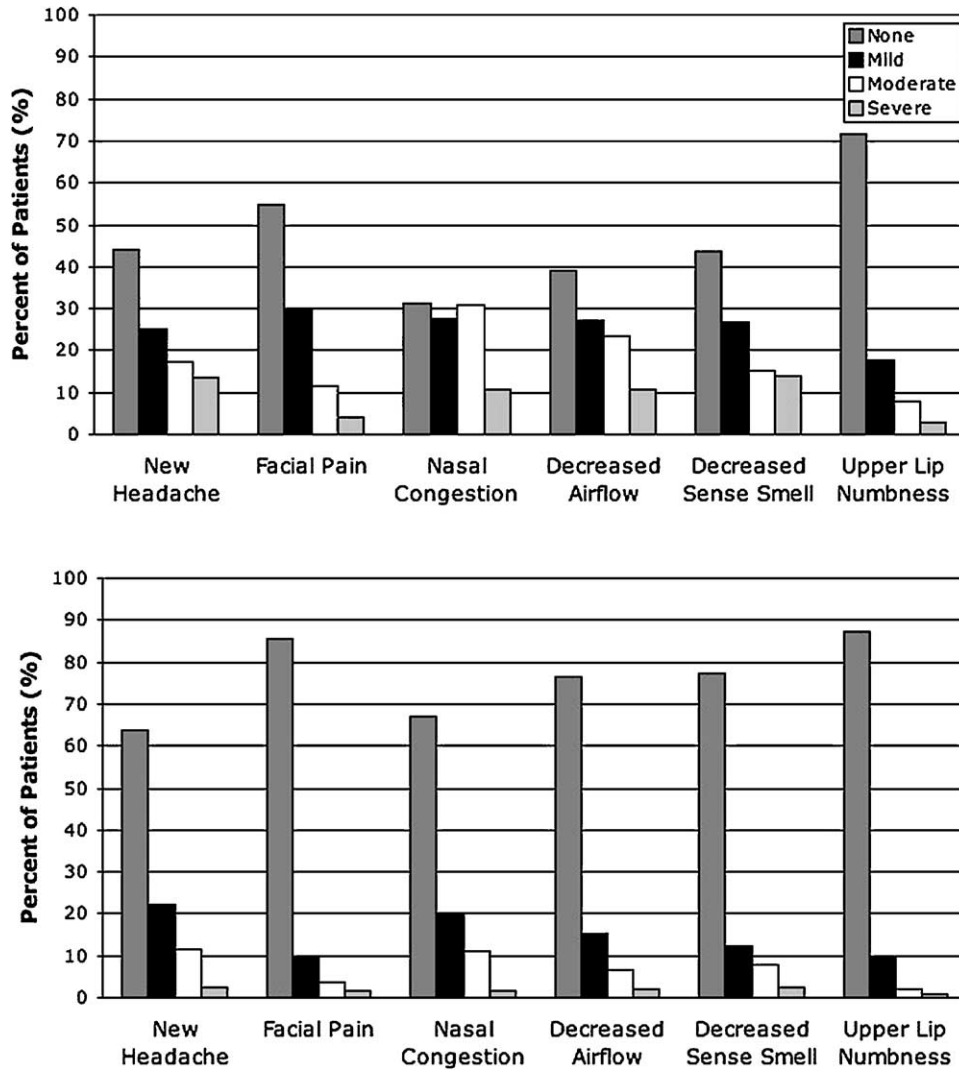


Fig. 2. Severity of postoperative headache, facial pain, and sinonasal complaints for all 259 patients surveyed at 2 weeks (upper) and 3 months (lower) after surgery. For all complaints, the improvement from 2 weeks to 3 months was statistically significant ( $P < .001$ ).

patients not returning to work met one or more of the following criteria: (1) multiple surgical procedures for tumor removal ( $n = 11$ ), (2) subsequent stereotactic radiosurgery,

fractionated radiotherapy, or chemotherapy ( $n = 8$ ), (3) age over 60 years ( $n = 8$ ), (4) Cushing’s disease ( $n = 8$ ), (5) new or preexisting panhypopituitarism ( $n = 7$ ), or (6) had

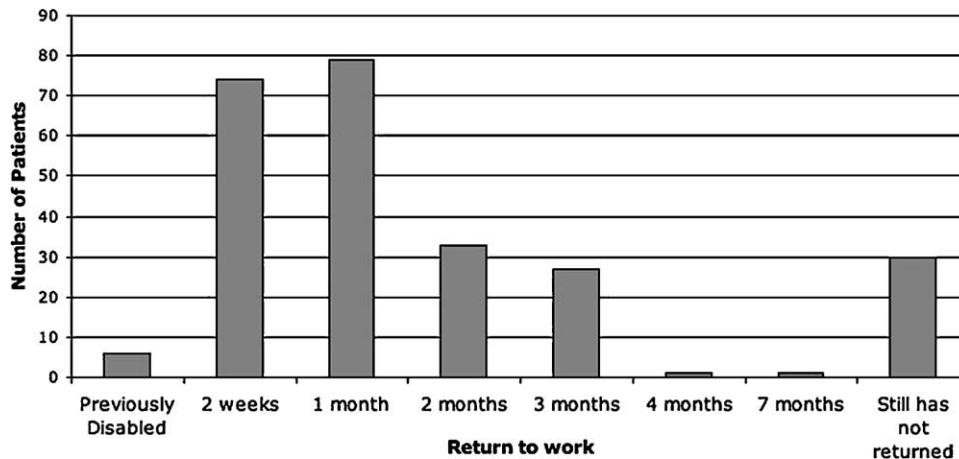


Fig. 3. Return to work in 259 patients.

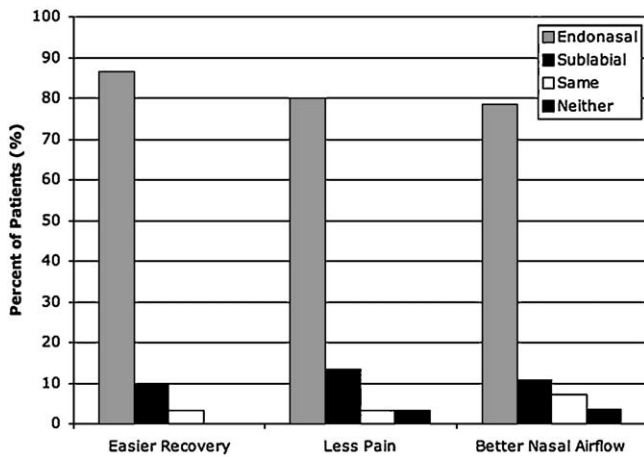


Fig. 4. Patient impressions of endonasal vs sublabial approach in 30 patients ( $P < .001$  for all comparisons).

surgical complications ( $n = 6$ , including 4 with permanent diabetes insipidus, 1 with delayed hyponatremia requiring readmission, and 1 with postoperative epistaxis requiring sphenopalatine artery embolization). Upon review of follow-up clinic notes, it was noted that these 30 patients in general failed to return to work because of persistent weakness, fatigue, and/or headache, and that none had new or persistent neurological disability.

The Rasch model root mean square error value was 0.11, which indicates that “the data fit the model, and that all misfit in the data is merely a reflection of the stochastic nature of the model. This is a ‘best case’ reliability, which reports an upper limit to the reliability of measures based on this set of items for this sample” [30]. In addition, the item separation reliability value (“equivalent to KR-20, Cronbach Alpha, and the Generalizability Coefficient” [30]) was 0.98. These indicate that the questionnaire items were internally consistent and met criteria for good testing based on the quality control fit statistics provided by the Rasch quality control and psychometric testing model [6,40].

### 3.3. Subgroup analyses

#### 3.3.1. Nasal packing vs no nasal packing

Of the first 79 patients who had nasal packing and who completed questionnaires, there was an increased percentage of patients who said the overall experience was the same (27%) or worse (15%) than expected compared with the subsequent 180 patients who did not have nasal packing (15.5% and 5%, respectively;  $P = .001$ ). Regarding the in-hospital postoperative period, more than 72% of patients with packing complained of the packing, its removal, and/or mouth breathing. At 2 weeks after surgery, patients with packing complained less about nasal congestion and decreased nasal airflow compared with those without packing ( $P = .019$  and  $P = .009$ , respectively), but by 3 months, this difference was lost ( $P$  values all  $> .1$ ).

#### 3.3.2. Comparison with sublabial approach

Of 30 patients who had a previous sublabial procedure, median hospital length of stay for that hospitalization was 5 days (range, 1–35 days) (Fig. 1), compared with 3 days for all patients undergoing the endonasal approach ( $P < .001$ ). Only 38% of patients went home within 4 days of their sublabial surgery, whereas 86% went home within 4 days for all endonasal procedures ( $P < .001$ ). Patients preferred the endonasal approach because it afforded an easier recovery (87%), was less painful (80%), and resulted in better nasal airflow (79%) ( $P < .0001$  for all comparisons) (Fig. 4).

#### 3.3.3. Extended approach

Of 15 patients with an extended transsphenoidal suprasellar approach, 64% said the overall experience was better than expected, 21% said it was the same, and 14% said it was worse ( $P = .64$ , compared with other patients). Median hospital length of stay for these patients was 5 days (range, 4–7 days), compared with 3 days (range, 1–25 days) for all patients ( $P < .001$ ). In total, 47% were discharged by hospital day 4.

In patients with preoperative headache, 30% had complete resolution, 50% had partial resolution, and 20% reported no change. When compared with patients without an extended approach, the rating of postoperative headaches was similar ( $P = .45$ ). As with other patients, facial and sinonasal complaints after surgery declined from 2 weeks postoperatively to 3 months postoperatively. At 3 months postoperatively, the responses of these patients were similar to those without an extended approach ( $P = .11$ , .71, .08, .33, .69, and .92, respectively).

#### 3.3.4. Patients with complications

Of patients who had surgical or other postoperative complications, 64% said the experience was better than expected, 29% said it was the same, and only 7% said it was worse ( $P = .41$ , compared with patients without complications). Median hospital stay was 4 days (range, 1–25 days), compared with 3 days for all patients ( $P < .001$ ). In total, 54% were discharged by hospital day 4. Postoperative headache and rhinological complaints decreased in severity from 2 weeks to 3 months postsurgery (Fig. 5). At 3 months, rates of new headache ( $P = .38$ ), facial pain ( $P = .81$ ), nasal congestion ( $P = .79$ ), nasal airflow ( $P = .77$ ), and lip numbness ( $P = .40$ ) were similar to patients without complications; however, more patients complained of moderate (22%) or severe (11%) decreased sense of smell ( $P < .001$ ).

#### 3.3.5. Patients requiring alotomy

Only 16% of surveyed patients required a small relaxing alar incision (alotomy). An alotomy has not been performed in the last 172 patients in the series. There have been no complications or specific complaints attributable to alotomy. Patients with an alotomy had no significant difference in

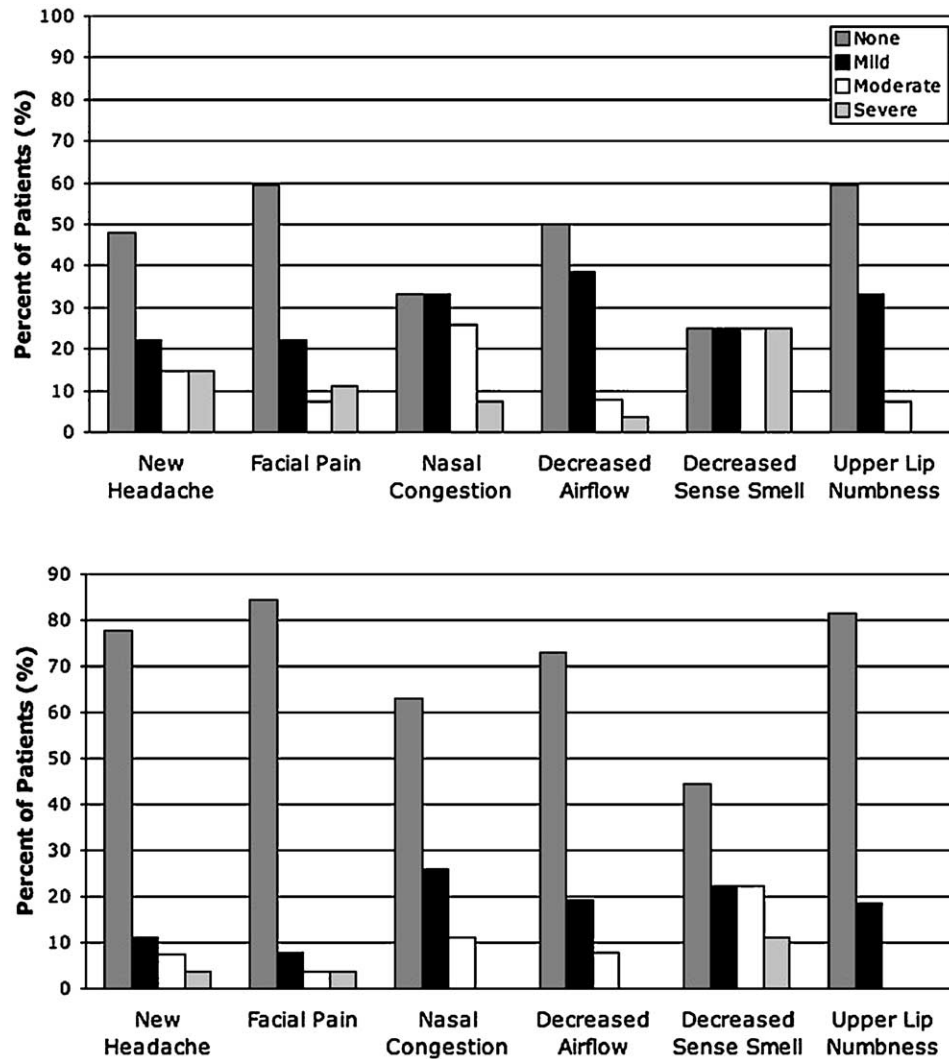


Fig. 5. Frequency of postoperative headache, facial pain, and sinonasal complaints at 2 weeks (upper) and 3 months (lower) after surgery for 28 patients with complications. Decreased sense of smell was more common in this group at 3 months or more compared with patients without complications ( $P < .001$ ).

general experience with the surgical procedure, and their sinonasal complaints at 2 weeks and 3 months or more after surgery were no different from other patients (all  $P$  values  $>.05$ ) with the exception of upper lip numbness. There was a small increase reported of mild and moderate upper lip numbness at 3 months or more after the procedure in those patients with alotomy ( $P = .04$ ). There was no difference in their length of hospital stay or return to work (all  $P$  values  $>.05$ ).

### 3.3.6. Patients with Cushing's disease

Of the 35 patients with Cushing's disease who underwent endonasal surgery and completed surveys, there was no significant difference in the overall experience or in the frequency of sinonasal complaints at 2 weeks or 3 months or more compared with other patients (all  $P$  values  $>.05$ ). However, patients with Cushing's disease had a slower recovery, as only 38% had returned to school or work by

1 month and 50% by 2 months (compared with 63% and 75% in other patients, respectively;  $P = .003$  and  $.001$ ).

## 4. Discussion

### 4.1. Summary of results

This study of 259 patients' postoperative impressions demonstrates that both the standard direct endonasal approach and the extended suprasellar approach are well tolerated with relatively few long-term rhinological complaints. Eliminating the use of nasal packing was associated with a significantly more favorable inhospital experience but more nasal congestion at 2 weeks after surgery. By 3 months or more after surgery, 67% to 87% of all patients in the cohort had no rhinological complaints and only 1% to 2% had severe rhinological complaints. Persistent nasal congestion, either moderate (11%) or severe (2%), was the most

common long-term complaint, and upper lip numbness, either moderate (2%) or severe (1%), was the least common.

Subgroup analysis revealed several interesting findings. In patients with prior sublabial surgery, the endonasal approach afforded a shorter hospital stay and a recovery characterized by less pain and better nasal airflow. Of those patients with a relaxing alar incision (alotomy), it was well tolerated without cosmetic problems, although there was a slight increase in associated upper lip numbness. This incision is, however, rarely used currently given the variety of speculum sizes now available. Regarding the extended suprasellar approach, although the risk of anosmia is theoretically greater because of a more cephalad dissection along the ethmoid sinus and olfactory rootlets, only two (15%) patients in this group complained of a moderate decrease in sense of smell. However, we have seen anosmia in at least one additional patient undergoing the extended approach for a meningioma who did not complete a questionnaire. In contrast, for unclear reasons, decreased olfaction was seen more frequently in patients with surgical complications, with 33% of this subgroup complaining of either moderate or severe decreased sense of smell. Finally, in patients with Cushing's disease, the interval to return to work was significantly longer compared with the overall cohort, which is not surprising given the relatively severe degree of disability these patients typically have.

#### 4.2. *The sublabial and transseptal transsphenoidal approaches*

Compared with a transcranial procedure, the transsphenoidal route, in general, is considered by many to be minimally invasive. So in some ways, one may question what is significant about this endonasal modification over the sublabial approach, which has proven to be so safe and effective [20–22,31,32]. However, the oral incision, mucosal dissection, and requirement for nasal packing after the sublabial route result in a relatively high rate of postoperative discomfort and sinonasal complications such as nasoseptal perforation, septal abscess, synechiae, upper lip paresthesias, and anosmia [10,15,29,34,35,37]. Previous reports of patients undergoing a sublabial approach document nasoseptal perforations in 1% to 13% of patients [15,35], upper lip numbness in 5% to 40% of patients [5,15,34], and anosmia in 5.5% of patients [35]. Detailed surveys such as ours documenting patient impressions are lacking in most of these reports [10,15,29,35].

The transseptal approach, which requires creation of an anterior septal mucosal tunnel, has also been associated with nasal complication rates of up to 21%, including septal perforation (7%), synechiae (12%), and septal abscess (1%) [37,38]. Some studies have concluded that the transseptal approach improves patient satisfaction compared with the sublabial approach; however, the basis of this conclusion is unclear given that these studies lacked surveys of patients undergoing a transseptal approach or comparison with patients with a sublabial approach [5,19,33]. One report

by Spencer et al [38] found that the transseptal approach resulted in increased upper lip numbness, scarring, and sinusitis compared with the sublabial route, and concluded that there was little difference in patient impressions between the sublabial and transseptal approaches. Although our survey did not ask patients with a prior transseptal approach to compare their experience with the direct endonasal approach, given the findings by Spencer et al [38], it is likely that their impressions would be similar to those having a prior sublabial approach.

#### 4.3. *Endonasal approaches—microscopic vs endoscopic*

One current point of controversy for which there appears to be no objective data is whether the direct endonasal approach as described here is comparable in terms of rhinological recovery to the purely endoscopic approach described by Cappabianca et al [7,8], Jho and Alfieri [23,24], and others [9,28,36,39]. Although at first glance it may appear that the purely endoscopic approach would result in fewer rhinological complaints and complications than the endonasal microscopic approach, this presumption may not be correct. Placement of the nasal speculum and out-fracturing of the ipsilateral middle turbinate during the endonasal microscopic approach can certainly lead to rhinological trauma that is not present in the purely endoscopic approach. However, once in position, the nasal speculum provides a protective sleeve to the nasal mucosa, the septum, and the turbinates. In contrast, there is no such protection during purely endoscopic procedures leaving the nasal mucosa vulnerable to the many in-and-out maneuverings of the rigid endoscope and other instruments. Hopefully, surveys such as ours will be similarly applied to patients undergoing purely endoscopic transsphenoidal surgery to address this issue.

#### 4.4. *Study limitations*

There are three major limitations to this study. First, although it was our intent to survey all patients who had endonasal surgery, logistical and patient-related issues made this impossible. Although we believe the patients surveyed represent a random cross-section of our patients, the potential for sampling bias was present. If we had obtained questionnaires only on patients without complications, the results would be swayed toward patients with generally better outcomes. However, the proportions of patients with complications that were surveyed and were not surveyed were similar. In addition, by including a subanalysis of patients with and without complications, we believe this issue was effectively addressed. Although these patients did have a longer hospital stay, more frequent CSF diversion, and more complaints of anosmia, in all other respects, their impressions did not differ from those of patients without complications.

Second, because routine postoperative rhinological inspections were not performed, it is possible that nasal-septal perforations, synechiae, or other sinonasal trauma

were not discovered. In particular, such findings may have been present in those patients who complained of persistent facial pain, nasal congestion, decreased airflow, or decreased sense of smell. However, given that only three patients in the entire cohort of 452 patients had endoscopic sinus surgery to address a persistent postoperative problem, correctable rhinological complications appear to be uncommon with this approach.

Third, although the questionnaire items were internally consistent and met criteria for good testing based on the quality control fit statistics provided by the Rasch model, the questionnaire was retrospective with respect to patients' impressions 2 weeks after surgery. Although this raises the question of possible "softening" of one's impressions of the early postoperative surgical experience, there was an almost unanimous decrease in the severity of complaints from the 2-week time point to 3 months or more time point after surgery. Without prospective testing at the 2-week time point, we know of no psychometric analysis for assessing this softening issue or, alternatively, "hardening" of one's early postoperative impressions.

## 5. Conclusions

Patient impressions and complaints are an often trivialized measure in assessing the overall success of a given operation. Yet, this aspect of surgery is becoming increasingly important to patients and one to which surgeons must attend [17]. The direct endonasal transsphenoidal approach with the operating microscope is associated with a rapid rhinological recovery and a low occurrence of serious long-term sinonasal complaints. Because it obviates the oral incision, extensive mucosal dissection, and nasal packing required of the sublabial transsphenoidal approach, it appears to afford a rhinologically superior patient recovery with fewer sinonasal complaints and a shorter hospital stay. However, not surprisingly, in a small minority of patients, significant discomfort persists after the direct endonasal approach. Whether a purely endoscopic endonasal approach can eliminate such complaints remains to be proven.

## References

- [1] Abe T, Ludecke DK. Recent primary transnasal surgical outcomes associated with intraoperative growth hormone measurement in acromegaly. *Clin Endocrinol (Oxf)* 1999;50:27-35.
- [2] Abe T, Ludecke DK. Transnasal surgery for infradiaphragmatic craniopharyngiomas in pediatric patients. *Neurosurgery* 1999;44:957-64.
- [3] Abe T, Ludecke DK. Transnasal surgery for prolactin-secreting pituitary adenomas in childhood and adolescence. *Surg Neurol* 2002;57:369-78.
- [4] Abe T, Tara LA, Ludecke DK. Growth hormone-secreting pituitary adenomas in childhood and adolescence: features and results of transnasal surgery. *Neurosurgery* 1999;45:1-10.
- [5] Arita K, Uozumi T, Yano T, et al. Oral complication of sublabial transsphenoidal approach and advantage of endonasal transsphenoidal approach. *No Shinkei Geka* 1994;22:119-24.
- [6] Bond TG, Fox CM. Applying the Rasch model: fundamental measurement in the human sciences. Mahwah (NJ): Lawrence Erlbaum; 2001.
- [7] Cappabianca P, Cavallo LM, Colao A, et al. Surgical complications associated with the endoscopic endonasal transsphenoidal approach for pituitary adenomas. *J Neurosurg* 2002;97:293-8.
- [8] Cappabianca P, Cavallo LM, Colao A, et al. Endoscopic endonasal transsphenoidal approach: outcome analysis of 100 consecutive procedures. *Minim Invasive Neurosurg* 2002;45:193-200.
- [9] Cho DY, Liao WR. Comparison of endonasal endoscopic surgery and sublabial microsurgery for prolactinomas. *Surg Neurol* 2002;58:371-5 [discussion 375-6].
- [10] Ciric I, Ragin A, Baumgartner C, et al. Complications of transsphenoidal surgery: results of a national survey, review of the literature, and personal experience. *Neurosurgery* 1997;40:225-36.
- [11] Cook SW, Smith Z, Kelly DF. Endonasal transsphenoidal removal of tuberculum sellae meningiomas: technical note. *Neurosurgery* 2004;55:239-344.
- [12] Das K, Spencer W, Nwagwu CI, et al. Approaches to the sellar and parasellar region: anatomic comparison of endonasal-transsphenoidal, sublabial-transsphenoidal, and transthemoidal approaches. *Neurol Res* 2001;23:51-4.
- [13] de Divitiis E, Cappabianca P, Cavallo LM. Endoscopic transsphenoidal approach: adaptability of the procedure to different sellar lesions. *Neurosurgery* 2002;51:699-705.
- [14] Dusick JR, Esposito F, Kelly DF, et al. The extended direct endonasal transsphenoidal approach for non-adenomatous suprasellar tumors. *J Neurosurg* 2005;102:831-41.
- [15] Eisele DW, Flint PW, Janas JD, et al. The sublabial transseptal transsphenoidal approach to sellar and parasellar lesions. *Laryngoscope* 1988;98:1301-8.
- [16] Esposito F, Becker DP, Villablanca JP, et al. Endonasal transsphenoidal transclival removal of prepontine epidermoid tumors: technical note. *Neurosurgery* 2005;56:E443 [discussion E443].
- [17] Gerszten PC. Outcomes research: a review. *Neurosurgery* 1998;43:1146-56.
- [18] Griffith HB, Veerapen R. A direct transnasal approach to the sphenoid sinus. Technical note. *J Neurosurg* 1987;66:140-2.
- [19] Guarnieri J, Moreau S, Cabal P, et al. Unilateral endonasal approach to hypophyseal adenomas. *Neurochirurgie* 1998;44:312-5.
- [20] Guiot G, Thibaut B. Excision of pituitary adenomas by transsphenoidal route. *Neurochirurgia (Stuttg)* 1959;1:133-50.
- [21] Hardy J. Surgery of the pituitary gland, using the open transsphenoidal approach. Comparative study of 2 technical methods. *Ann Chir* 1967;21:1011-22.
- [22] Hardy J. Transsphenoidal microsurgery of the normal and pathological pituitary. *Clin Neurosurg* 1969;16:185-217.
- [23] Jho HD. Endoscopic transsphenoidal surgery. *J Neurooncol* 2001;54:187-95.
- [24] Jho HD, Alfieri A. Endoscopic endonasal pituitary surgery: evolution of surgical technique and equipment in 150 operations. *Minim Invasive Neurosurg* 2001;44:1-12.
- [25] Kawamata T, Iseki H, Shibasaki T, et al. Endoscopic augmented reality navigation system for endonasal transsphenoidal surgery to treat pituitary tumors: technical note. *Neurosurgery* 2002;50:1393-7.
- [26] Kawamata T, Kamikawa S, Iseki H, et al. Flexible endoscope-assisted endonasal transsphenoidal surgery for pituitary tumors. *Minim Invasive Neurosurg* 2002;45:208-10.
- [27] Knappe UJ, Ludecke DK. Transnasal microsurgery in children and adolescents with Cushing's disease. *Neurosurgery* 1996;39:484-92.
- [28] Koren I, Hadar T, Rappaport ZH, et al. Endoscopic transnasal transsphenoidal microsurgery versus the sublabial approach for the treatment of pituitary tumors: endonasal complications. *Laryngoscope* 1999;109:1838-40.
- [29] Laws ER, Kern EB. Complications of transsphenoidal surgery. In: Laws ER, Randall RV, Kern EB, et al, editors. Management of pituitary adenomas and related lesions with emphasis on trans-

- sphenoidal microsurgery. New York: Appleton-Century-Crofts; 1982. p. 329–46.
- [30] Linacre JM, Wright BD. A user's guide to Bigsteps Rasch-model computer programs. Chicago: Winsteps.com; 2003.
- [31] Liu JK, Das K, Weiss MH, et al. The history and evolution of transsphenoidal surgery. *J Neurosurg* 2001;95:1083–96.
- [32] McDonald TJ, Laws Jr ER. Historical aspects of the management of pituitary disorders with emphasis on transsphenoidal surgery. In: Laws Jr ER, Randall RV, Kern EB, et al, editors. *The management of pituitary adenomas and related lesions with emphasis on transsphenoidal microsurgery*. New York: Appleton-Century-Crofts; 1982. p. 1–13.
- [33] Nasser SS, McCaffrey TV, Kasperbauer JL, et al. A combined, minimally invasive transnasal approach to the sella turcica. *Am J Rhinol* 1998;12:409–16.
- [34] Schoem SR, Khan A, Wilson WR, et al. Minimizing upper lip and incisor teeth paresthesias in approaches to transsphenoidal surgery. *Otolaryngol Head Neck Surg* 1997;116:656–61.
- [35] Sharma K, Tyagi I, Banerjee D, et al. Rhinological complications of sublabial transseptal transsphenoidal surgery for sellar and suprasellar lesions: prevention and management. *Neurosurg Rev* 1996;19:163–7.
- [36] Sheehan MT, Atkinson JL, Kasperbauer JL, et al. Preliminary comparison of the endoscopic transnasal vs the sublabial transseptal approach for clinically nonfunctioning pituitary macroadenomas. *Mayo Clin Proc* 1999;74:661–70.
- [37] Sherwen PJ, Patterson WJ, Griesdale DE. Transseptal, transsphenoidal surgery: a subjective and objective analysis of results. *J Otolaryngol* 1986;15:155–60.
- [38] Spencer WR, Levine JM, Couldwell WT, et al. Approaches to the sellar and parasellar region: a retrospective comparison of the endonasal-transsphenoidal and sublabial-transsphenoidal approaches. *Otolaryngol Head Neck Surg* 2000;122:367–9.
- [39] White DR, Sonnenburg RE, Ewend MG, et al. Safety of minimally invasive pituitary surgery (MIPS) compared with a traditional approach. *Laryngoscope* 2004;114:1945–8.
- [40] Wright BD, Masters GN. Rating scale analysis. Chicago: MESA Press; 1982.
- [41] Zada G, Kelly DF, Cohan P, et al. Endonasal transsphenoidal approach for pituitary adenomas and other sellar lesions: an assessment of efficacy, safety, and patient impressions. *J Neurosurg* 2003;98:350–8.

---

## Commentary

Articles from Dan Kelly's group from UCLA are always rigorous and effective, and this one confirms the tradition. Sublabial approach, with its three mucosal tunnels and the need of routine use of nasal packing, leaves the patient with a worse experience when compared with the endonasal approach. The authors reach this conclusion through the clear, convincing, and honest analysis of a questionnaire given to the patients after the operation.

Compared with the sublabial route, the endonasal approach is associated with less pain (80%), easier recovery (87%), better airflow (79%), and a shorter hospital stay (median 3 vs 5 days). Furthermore, the endonasal approach per se offers in 73% of patients a better experience than expected. It could be argued from the surgical perspective that the sublabial route may provide a "slightly" wider anatomical exposure than the endonasal approach, with subsequent advantages for the patients.

The recent widespread use of endonasal approaches extending from the planum sphenoidale to the clivus using the microscope, the endoscope, or both, has clearly demonstrated that the endonasal route can also provide a good exposure on areas beyond the sella. Furthermore, the use of endoscope, neuronavigator, microdoppler probe, and the refinement of microinstruments have permitted transsphenoidal surgery to be even more safe and effective. In an era when technology has been the biggest change in surgical procedures, a "slight" difference is not a valid reason for choosing a more invasive procedure instead of a less invasive one, as is the endonasal approach. Patients gave their opinion: they preferred the minimally invasive endonasal route.

Beyond our personal considerations, which have already been reported elsewhere concerning our favor for the endoscopic transsphenoidal surgery with respect to the microscopic technique, the work of the authors seems appropriate, well-timed, and supported by proper data on the opportunity that today, for transsphenoidal surgery, the endonasal technique should be preferred to the sublabial one, which is still practiced in too many centers.

Paolo Cappabianca, MD

*Department of Neurological Sciences  
Universita degli Studi di Napoli Federico II  
80131 Napoli, Italy*

Dusick et al in this study have chosen to address a very difficult area of medicine, the area of assessing the success of a treatment intervention based on the patient's perspective. As we are all well aware, a patient's perspective is influenced by numerous factors, many of which have little to do with clinical outcome. We have clearly entered an era of medicine where patients' impressions and complaints are becoming increasingly important. Although the study is not perfect, it is well done. In this study, 259 of a possible 452 patients who underwent endonasal surgery between July 1998 and April 2005 responded to a series of questionnaires. From these questionnaires, it is clear that the endonasal approach is associated with a high patient satisfaction rate (73% reporting a better than expected experience compared with only 8% reporting a worse than expected experience), a low rate of complications, and a short hospital stay (86% of patients discharged by hospital day 4). When compared with the sublabial approach, the endonasal approach resulted in a statistically significant shorter hospital stay (median 3 vs 5 days) and a statistically significant improvement in the patient's overall impression. For patients undergoing the endonasal approach and receiving nasal packing, their overall experience was not as favorable as those who did not have packing. At 2 weeks, however, these patients complained less about nasal congestion and decreased airflow,